

- Fig. 2. Diagrammatic view of the sensory canal system in the head of *Amiurus*. (Lettering as above.)
- Fig. 3. Figure showing the series of canal-bones, *c.b.*, in *Amiurus*, which connect the main canal of the head with the operculo-mandibular branch. From the series of canal-bones, *c.b.*, the canal passes first into a portion of the hyomandibular, *hyom.*, then into the preoperculum, *p.op.*, and finally into the quadrate, *qu.*
- Fig. 4. Diagrammatic view of the sensory canal system in the head of *Pimelodus*. (Lettering as before.)
- Fig. 5. Dendritic branches and grooves from the sub-orbital and operculo-mandibular branch of the main sensory canal of *Pimelodus*.
- Fig. 6. Lateral view of the head of *Callichthys littoralis*, showing the distribution of the sensory canal system.
- Fig. 7. Lateral view of the head of *Labeo dussumieri*, showing the distribution of the sense-organs. $\times 1$. (Drawn by Mr. F. W. Crispe.)
- Fig. 8. Longitudinal section through one of the flask-shaped sense-organs in *Labeo dussumieri*, showing the pore, *p.*, and the sensory filaments, *s.fl.*, arising from the walls of the cavity. The nerve innervating the sense-organ is shown at the base, *n.f.*
- Fig. 9. Sensory filament, highly magnified; the nerve fibre, *n.f.*, passes up the filament for nearly two-thirds of its length and then divides into a number of very fine branches, which terminate around the disc, *d.*
- Fig. 10. Diagrammatic view of the sensory canal system in the head of *Esox* and distribution of the trigeminal and facial nerves.
- Fig. 11. Lateral diagrammatic view of the same.
- Fig. 12. Diagram illustrating the distribution of the mandibular branches of the trigeminal and facial nerves in *Esox*.
- Fig. 13. Lateral diagrammatic view of the sensory canal system in *Salmo*.
- Fig. 14. Dorsal view of the same. The sensory canals are coloured yellow. Those canals which are no longer functional and pass through the cranial elements are indicated by a double black line.
- Fig. 15. Canal-bones from the main canal of the head of *Salmo*.
- Fig. 16. Dorsal diagrammatic view of the sensory canal system of *Conger* and innervation of the same. The figures 1 to 6 indicate the saccular dilatations. *r.op.*, Ramus opercularis. Other lettering as above.
- Fig. 17. Lateral diagrammatic view of the same.
- Figs. 18, 19. Cartilages from the occipital commissure of the sensory canal system of *Conger*.

2. Remarks on some Cranial Characters of the Salmonoids.

By G. A. BOULENGER, F.R.S.

[Received March 27, 1895.]

Various attempts have been made to split up the Salmonoids into families and subfamilies. In his classification of 1871¹, Prof. Cope proposed to separate the Coregonidæ from the Salmonidæ owing to their having the parietal bones united in front of the supraoccipital, whilst they are separated by the latter bone in the Salmonidæ proper. In a recent paper, Dr. T. Gill² controverts Cope's statement, remarking that "on examination of a skull of *Coregonus*" he finds the same relation of the bones as in *Salmo*, whilst the arrangement ascribed to *Coregonus* is character-

¹ Trans. Amer. Philos. Soc. (2) xiv. 1871, p. 454.

² Proc. U.S. Nat. Mus. xvi. 1894, p. 117.

istic of *Thymallus*. For this reason *Coregonus* is retained in the Salmonidæ and *Thymallus* is raised to family rank; the author adding that the Thymallidæ are further distinguished from the Salmonidæ by the presence of epipleurals and the greater development of the dorsal fin, many of the anterior rays of which are unbranched. The last feature, by itself, is too trivial to be used as a family character; and the first characteristic is unfounded, *Salmo* and *Coregonus* having well-developed epipleurals.

As to the condition of the parietal bones, it seems curious that there should be divergence of opinion on a point so easy to ascertain even in spirit-specimens. It is not stated to what species of *Coregonus* the skull belongs on which Gill's observation is based, but all the examples I have examined in the British Museum, skeletons and alcoholics, of European and American species of that genus, show the parietals forming a more or less extensive suture between the frontals and supraoccipital, as ascertained by Cope. I am therefore at a loss to account for Gill's statement to the contrary.

I have also examined *Brachymystax*, which, from its very small scales combined with a small mouth, holds a position intermediate between *Salmo* and *Coregonus*; the supraoccipital separates the parietals, as in *Salmo*.

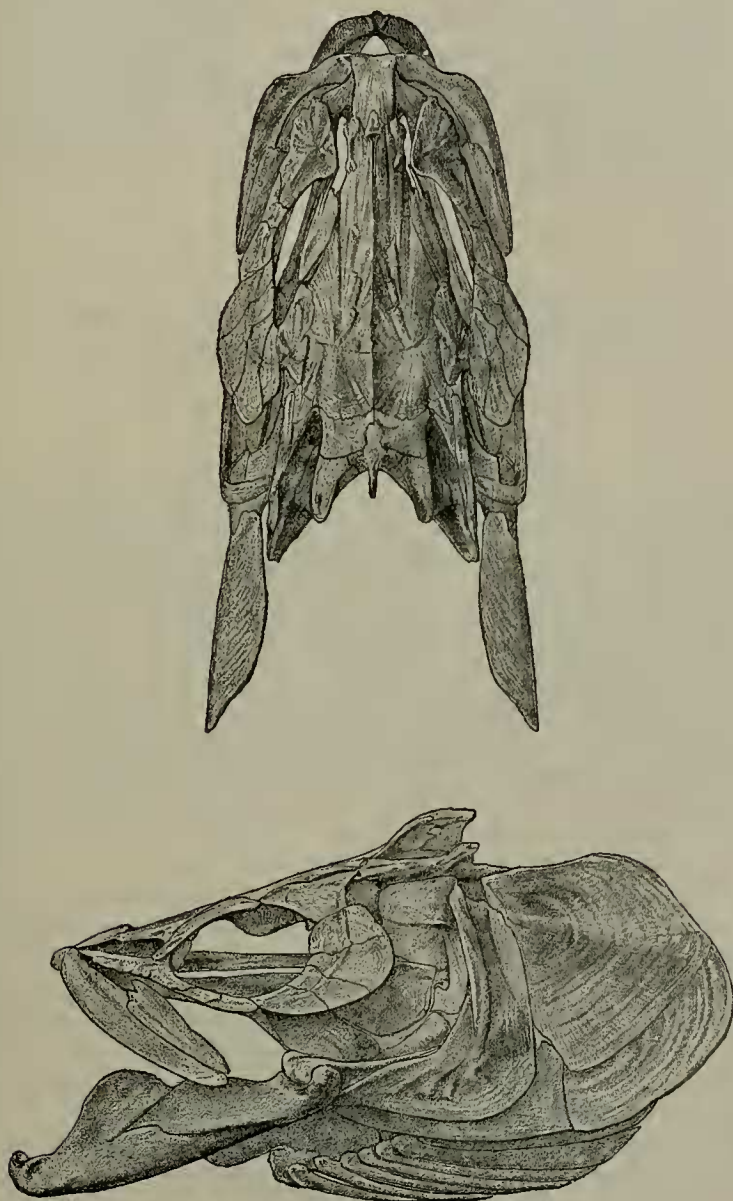
In his paper quoted above, Gill founds a subfamily, Stenodontinæ, in the family Salmonidæ, for the curious genus *Stenodus*, Rich. (*Luciotrutta*, Gthr.), without having been able, however, to examine the skeleton. A large head of the "Inconnu," *Stenodus mackenzii*, from the Mackenzie River, was presented by Mr. Walter Gordon Cumming to the Museum a few weeks ago, and I have had it prepared as a skull in order to supplement this gap in our knowledge of Salmonoid osteology. This skull is here figured.

It will be seen that Gill's statement, "lower jaw articulating with the quadrates behind the eyes," is not quite correct, the articulation of the mandible falling below the posterior border of the orbit, in this respect intermediate between *Salmo* and *Coregonus*. The posterior process of the quadrate is very long and slender. The supraorbital is very large and in contact with the postorbital. But what is especially noteworthy is the condition of the supraoccipital and parietals, the latter bones forming a very short suture, separating the former from the frontals, a condition which is, in fact, intermediate between the two types mentioned above. On examining a smaller specimen of *Stenodus mackenzii* and a specimen of the Russian *S. leucichthys*, I find no union whatever between the parietals, and therefore the character to which Cope and Gill have attached so great an importance falls to the ground.

It must be remarked, however, that, as I have ascertained by removing the parietals in specimens of *Coregonus williamsonii*, the supraoccipital joins the frontal. Therefore even in *Coregonus* and *Thymallus* the relation is a widely different one from that obtained in Cyprinoids and Characinoids, the apparent resemblance being merely due to the fact that in the Salmonoids in question the

parietals extend over the supraoccipital, whilst in *Salmo* they are the frontals which overlap the supraoccipital.

Fig. 1.



Upper and side views of the skull of *Stenodus mackenzii*. ($\frac{1}{2}$ nat. size.)

The result of the investigation that I have undertaken is that there is no reason for separating *Coregonus* and *Thymallus* from the Salmonidæ.

I also wish to observe on this occasion that the Percopsidæ, which are not included in Cope's synopsis and are placed in "Suborder uncertain" by Gill, are most nearly allied to the Salmonidæ. As in *Salmo*, the supraoccipital completely separates the parietals. Prof. Stewart, who has kindly examined bones of *Percopsis guttatus* and *Columbia transmontana* at my request, informs me that he has been unable to find a trace of lacunæ, although these are present in the bones of *Salmo*, *Coregonus*, *Thymallus*, *Stenodus*, *Microstoma*, and *Argentina*; he, however, finds them likewise absent in *Osmerus*, *Hypomesus*, *Retropinna*, *Salanx*, and *Plecoglossus*.

3. On certain Features in the Skull of *Osteoglossum formosum*. By Prof. T. W. BRIDGE, M.A.¹

[Received March 28, 1895.]

(Plate XXII.)

While recently examining a skeleton of a specimen of *Osteoglossum formosum*, Müll. et Schl., in the Zoological Museum of Mason College, I noticed one or two interesting features in connection with the skull which, so far as I have been able to discover, have not previously been described. The only reference to the skull with which I am acquainted is by Hyrtl in his "Beitrag zur Anatomie von *Heterotis ehrenbergii*, C.V." (Denkschr. d. Akad. Wiss. Wien, Bd. viii. 1854, pp. 73-88). In this paper the author briefly compares the skeleton of *Osteoglossum* with that of *Heterotis*; but although the comparison extends to certain features in the structure of the skull in the two genera, Hyrtl makes no reference whatever to those structural modifications in the skull of *Osteoglossum* to which I desire to direct attention.

On examining the base of the skull of *Osteoglossum formosum* the parasphenoid (Pl. XXII. figs. 1 and 2, *ps.*) is seen occupying its normal position, firmly attached to the ventral surface of the basioccipital behind, and, from that point, extending forwards beneath the cartilaginous interorbital region to its junction with the dentigerous vomers anteriorly. As the parasphenoid passes between and beneath the two prootic bones it forms the floor of a median canal for the muscles of the eyeball, the roof of which is, as usual, formed by the mesial union of the two prootics in the floor of the cranial cavity. At this point the parasphenoid gives off from its lateral margins two well-marked processes on each side: first, an ascending process (*ps.l.*) which passes obliquely upwards, in contact with the anterior margin of the prootic of its side, and finally terminates above by overlapping the outer surfaces of the prootic (*pr.o.*), the sphenotic (*sp.o.*), and the

¹ Communicated by Dr. GÜNTHER, F.R.S.